

A RARE CASE OF OVARIAN MIXED GERM CELL TUMOR WITH CHORIOCARCINOMA PRESENTING AS RUPTURED ECTOPIC PREGNANCY

1. Dr Preetha F Nayakar. (PG student)

2. Dr Rekha R . Asst Prof

Dept OBG, Shivamogga Institute of Medical Sciences, Shivamogga, Karnataka.

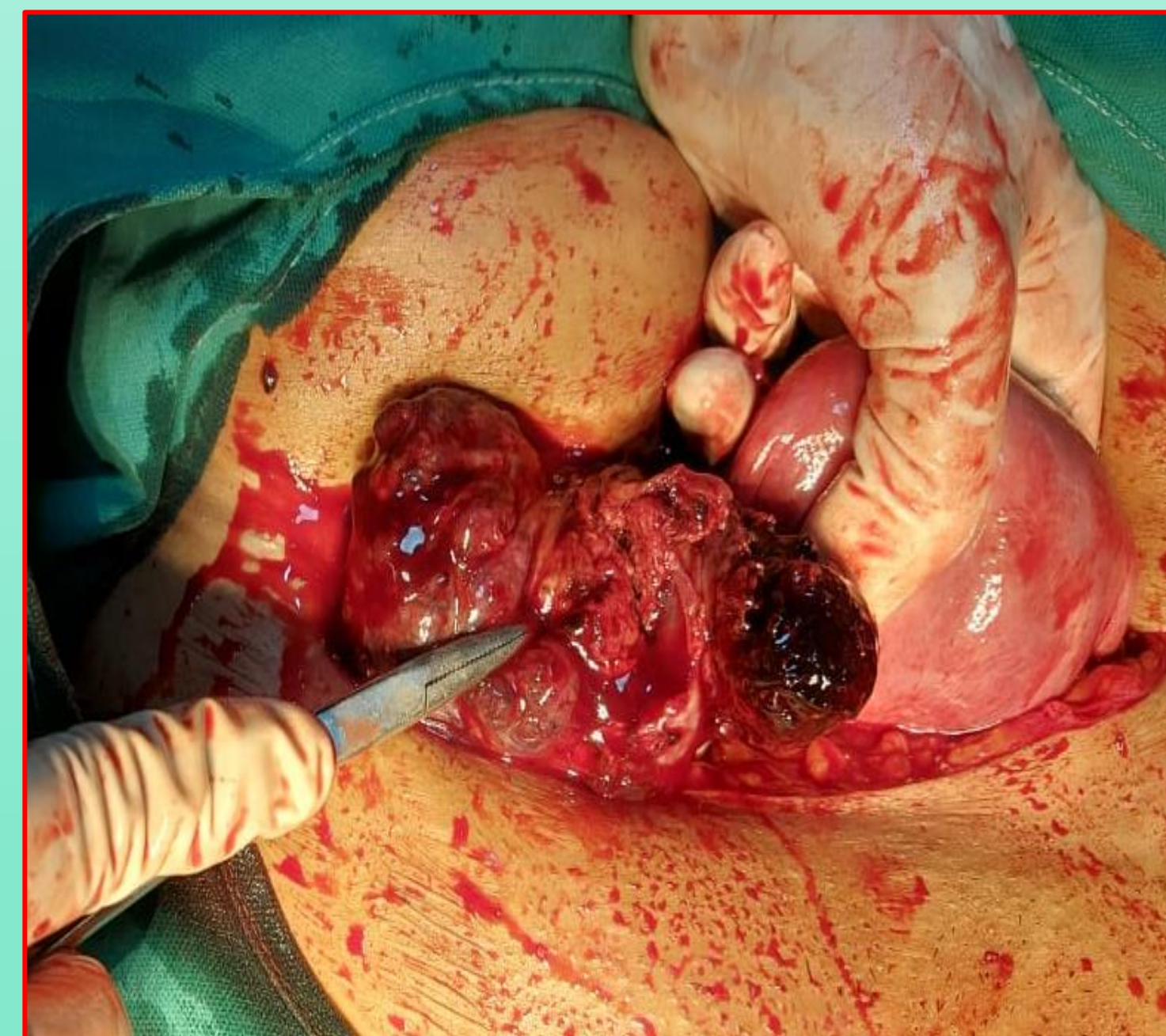INTRODUCTION: Ovarian germ cell tumor comprise approximately 15-20 % of all the ovarian neoplasms and malignant germ cell tumor less than 5%. The incidence of malignant germ cell tumor ranges from 8-19 % in Asia and 1 to 6 % in India. Mixed germ cell tumor contain two or more recognizable germ cell entities eg combination of dysgerminoma, gonoblastoma, teratoma , endodermal sinus tumor and choriocarcinoma. Mixed germ cell tumor with choriocarcinoma is extremely rare and this case is hence worth reporting, We performed right salphingoophrectomy and left tubectomy.

CASE REPORT: History: A 33 yr old lady P3 L3, not tubectomized came with c/o of irregular cycles since 6 months, Continuous bleeding PV since 10 days, Acute pain abdomen since 3 days. She gave an interesting history that, she was denied tubectomy thrice at the peripheral PHC as her UPT was +ve.

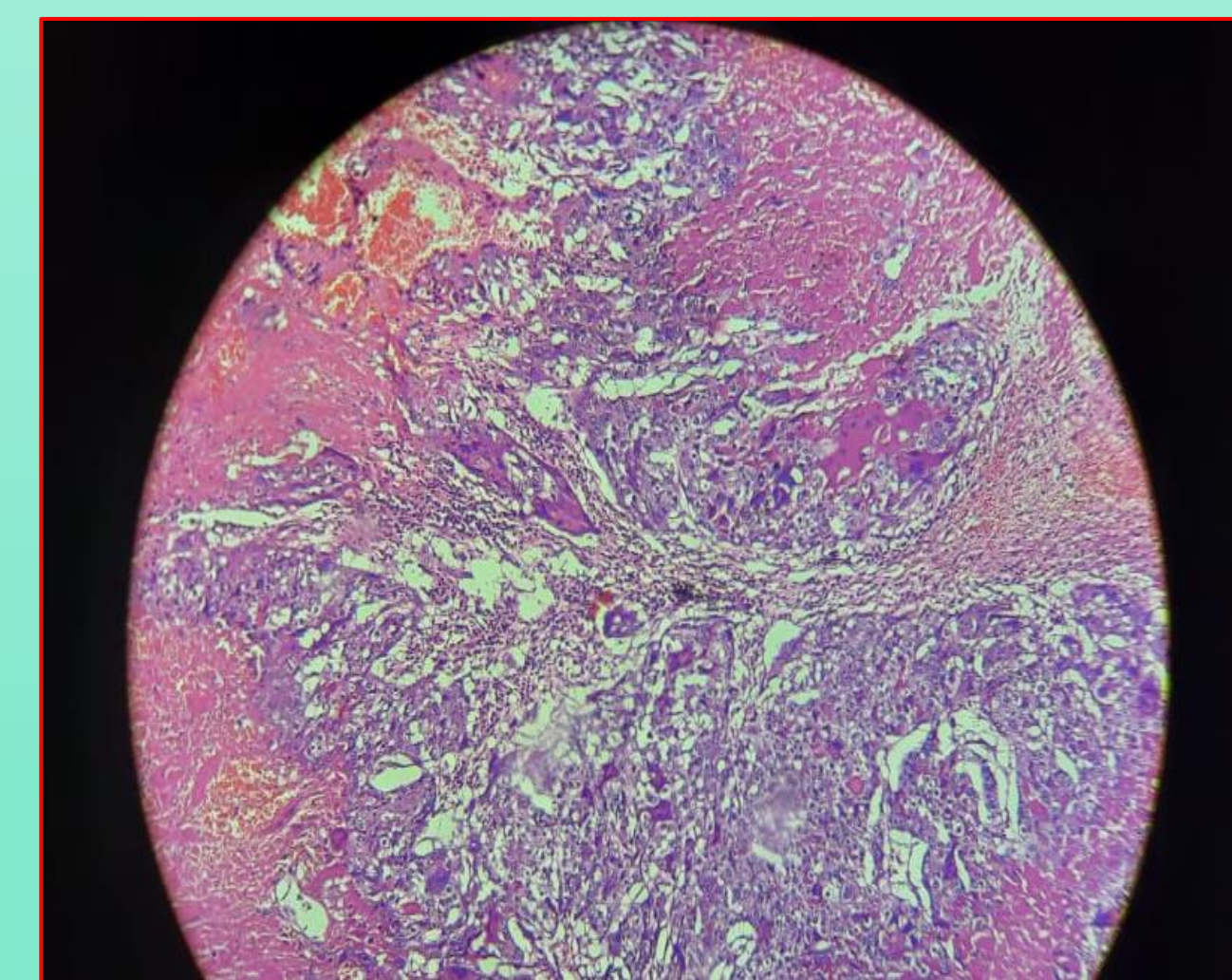
Married life : Married since 12yrs, P3 L3 not tubectomised . AOM- 12 yr LMP- 5/5/2021, Previous cycles were regular with moderate flow.

EXAMINATION: P/A-soft, Generalized tenderness over lower abdomen +, P/V- Right fornix fullness, culdocentesis-haemoperitoneum.

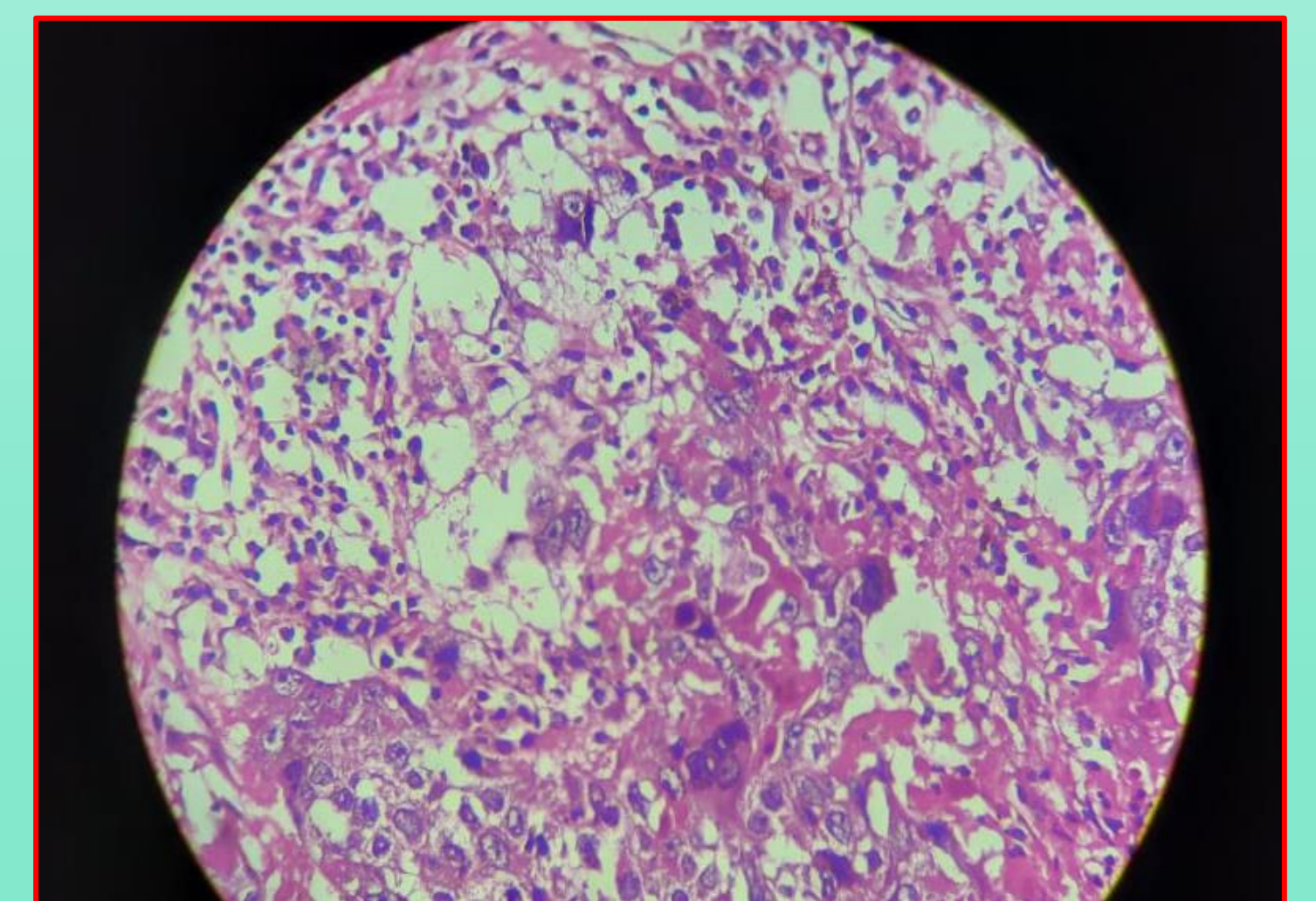
INVESTIGATION : UPT- +ve, LDH- 296 U/L, 28/5/21, B-HCG-70,400 miu/ml , AFP- 1.8 mg/ml, TSH- 1.2 iu/ml.(In view of +ve UPT and the presenting clinical scenario, this case could be easily mistaken for ruptured ectopic pregnancy, but very high values of β HCG prompted us to evaluate other tumor markers for germ cell tumor). **SCAN REPORT -** Ill defined heterogenous lesion in right adnexa measuring 6.2 x 4 x 3.6 cm showing peripheral vascularity. Minimal fluid is seen surrounding lesion. Right ovary not separately visualized. Minimal free fluid in pelvic and peritoneal cavity. **MRI-** Isodense right adnexal lesion noted 3x3.2cm with surrounding free fluid



Areas of hemorrhage and necrosis with syncytiotrophoblast



Poorly differentiated cells with large nucleus and prominent nucleoli



MANAGEMENT : ↓SAB, Laparotomy and proceed i.e right salphingoophrectomy and left tubectomy, Intra-OP findings-Right ovarian mass 6x6cm noted and 50 ml of haemoperitoneum noted, which was sent for cytology. Clots seen adherent to POD , bowel and posterior surface of broad ligament. Left fallopian tube and ovary were found to be normal. **HPR Report:** Mixed germ cell tumor with choriocarcinoma. Chemotherapy planned.

CONCLUSION: This case is interesting in two ways 1) for its rarity 2) for mimicking as ruptured ectopic pregnancy. Ruptured germ cell tumor and granulosa cell tumor should be considered as differential diagnosis as these cases present like ruptured ectopic pregnancy.